

ORIGINAL RESEARCH

Buddy Taping for Treatment of Ulnar Collateral Ligament Injuries: A Cadaveric Study

Aravind Athiviraham, MD, FRCS(C)¹; Ben Zellner, MD¹; Steve Hunt, MD²; Burton Ma, PhD²; Suriya Luenam, MD²; David Pichora, MD²; Conrad Watters, MD²

¹Department of Orthopaedic Surgery; Baylor College of Medicine, Houston, TX

²Queen's University; Kingston, ON; Canada

ABSTRACT

Introduction: The purpose of the study was to perform a biomechanical analysis of injuries of the ulnar supporting structures of the thumb metacarpophalangeal (MCP) joint and assess the effectiveness of buddy taping as a treatment.

Methods: Four fresh cadaveric hand specimens were studied. Two pins secured the metacarpal to a jig, one K-wire immobilized the interphalangeal joint, and another was driven 20 mm distal to the MCP joint to allow for constant bending moments between specimens. The joint was loaded in radial deviation using 1 kg of force. Each thumb underwent sequential division of the proper collateral ligament, accessory collateral ligament, and volar plate.

Results: The mean laxity in the control specimen was $12.25^\circ \pm 3.64$ and $16.00^\circ \pm 5.02$ at 0° and 30° thumb flexion, respectively. When the proper collateral ligament was sectioned, valgus laxity in extension was $33.33^\circ \pm 19.04$ and $39.75^\circ \pm 18.8$ in flexion. Dividing the accessory collateral ligaments produced a valgus laxity in extension of $46.67^\circ \pm 4.2$ and flexion of $44.67^\circ \pm 6.4$. Incising the volar plate produced a valgus laxity of $50.33^\circ \pm 8.7$ in extension and $48.33^\circ \pm 3.5$ in flexion. In all three groups, buddy taping produced a statistically significant decrease in valgus laxity in flexion with the index immobilized, but not with the index free.

Discussion: These results suggest that buddy taping may not be an effective treatment for patients with UCL injuries, given that the index is not immobilized with this technique.

Keywords: Buddy taping; Ulnar collateral ligament injury; Thumb injury.

INTRODUCTION

The ulnar and radial collateral ligaments are stabilizers of the thumb metacarpophalangeal (MCP) joints under stress. Injury leads to

pain and disability and can limit many activities of daily living. "Gamekeeper's thumb" describes a chronic overuse injury of the ulnar collateral ligament (UCL), whereas "skier's thumb" is an acute injury to the UCL (1). The UCL consists of both a proper and accessory collateral ligament. The injury results from a fall on an outstretched hand with forceful radial and palmar abduction of the thumb.

Corresponding Author:

Aravind Athiviraham, MD, FRCS(C)
Department of Orthopaedic Surgery
Baylor College of Medicine
7200 Cambridge St, Suite 10A
Houston, TX 77030, USA
e-mail: aravind.athiviraham@bcm.edu

Although thumb spica splints are commonly used for treatment of UCL injuries of the thumb, good results after functional bracing of ligamentous injuries of the MCP joint of the thumb have been reported (2,3). Functional bracing is particularly useful as definitive treatment for incomplete ruptures or interim treatment while awaiting surgery. However, functional bracing is limited by the lack of widespread availability. The purpose of the study was to assess the effectiveness of buddy taping as a functional brace for treatment of UCL injuries of the thumb by using a cadaveric model (Figure 1).

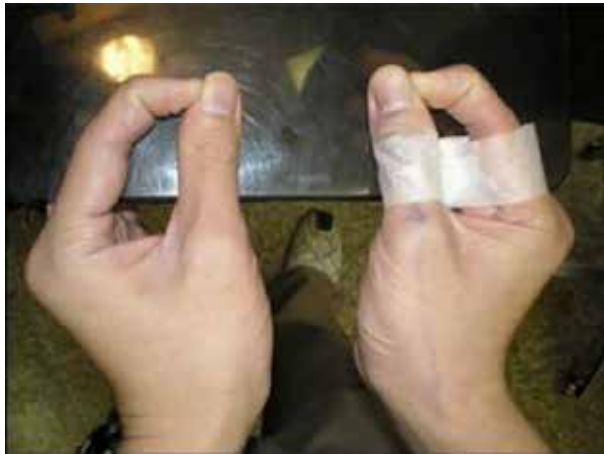

Figure 1. The application of buddy taping the thumb to the index as a functional brace for UCL injuries.

MATERIALS & METHODS

Four fresh cadaveric hand specimens were used in this pilot study. Two pins secured the first metacarpal to a jig (Figure 2). One K-wire immobilized the interphalangeal joint, and another was driven 20 mm distal to the MCP joint to allow for constant bending moments. The joint was valgus stressed using 1 kg of force. A control measurement was done, followed by sequential division of the proper collateral ligament (PC), accessory collateral ligament (AC), and volar plate

(VP). After each stage, valgus laxity (VL) was measured in both extension and 30° flexion, ± buddy taping, using fluoroscopy. Buddy taping involved taping the proximal thumb and index with 1 cm space. Measurements were obtained with 1) index MCP immobilized in 90° flexion, and 2) index MCP free. Independent samples t-test and standard deviation were computed with SPSS (version14). A p value of less than 0.05 defined significance.

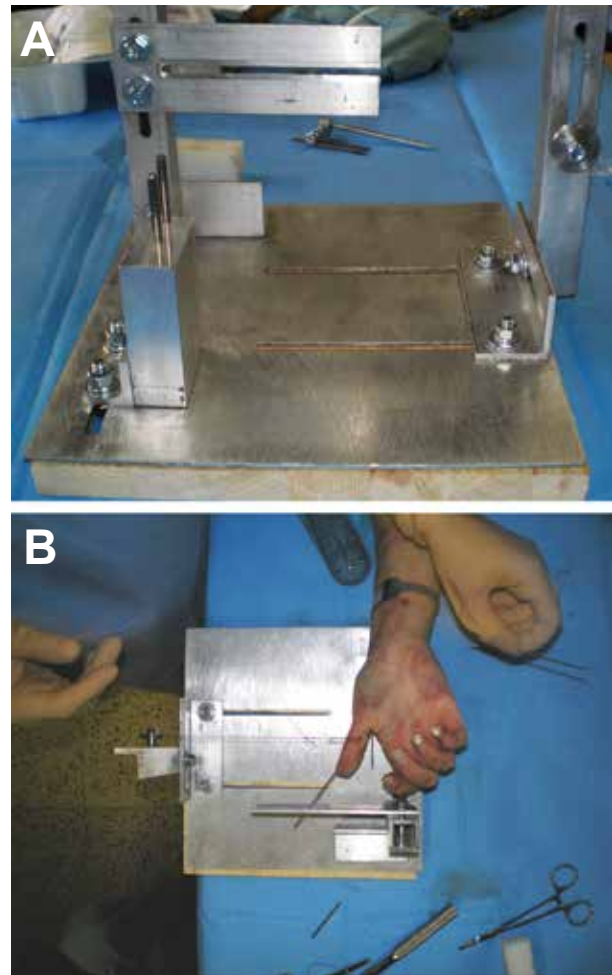


Figure 2. Custom-built jig used for the study (A). The first metacarpal was secured onto the jig to allow for constant bending moments (B).

RESULTS

Figure 3 demonstrates valgus stress at

30° of thumb flexion applied to the first MCP joint with a) the proper UCL incised, and b) buddy taping of the thumb to the index. The mean valgus laxity (MVL) in the control specimens was 12.3°±3.6 in extension (E) and 16.0°±5.0 in flexion (F). When the PC, AC, and VP were sectioned,

MVLE and MVLF were 33.3°±19.0 and 39.8°±18.8 (PC); 46.7°±4.2 and 44.7°±6.4 (AC); and 50.3°±8.7 and 48.3°±3.5 (VP) (Tables 1-3). In all three groups (PC/AC/VP), BT with the index immobilized produced a significant decrease in MVLE to 6.5°±4.9 (p=0.02), 8.5°±7.8 (p=0.03), and 3.0°±4.2 (p<0.01), and MVLF to 4.7°±4.5 (p<0.01), 9.5°±9.2 (p=0.04), 0° (p<0.01), respectively. With the index free, BT did not significantly reduce MVLE: 28.5°±5.0 (p=0.06)(AC), 37.5°±17.7 (p=0.49)(VP) or MVLF: 26.0°±5.7(p=0.18) (PC), 34.5°±14.9 (p=0.549)(AC), 40.7°±11.01 (p=0.313) (VP).

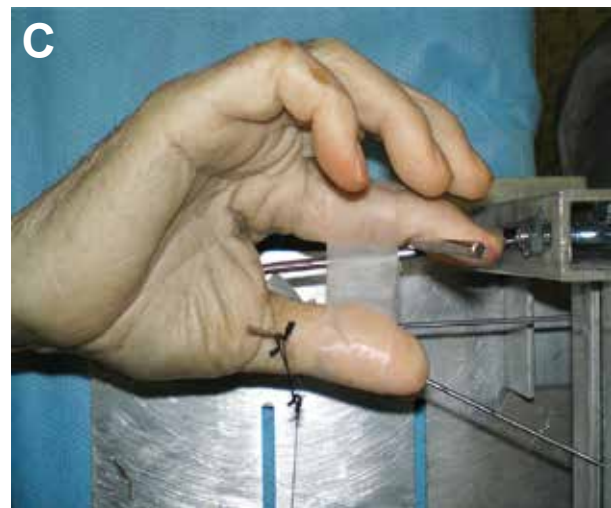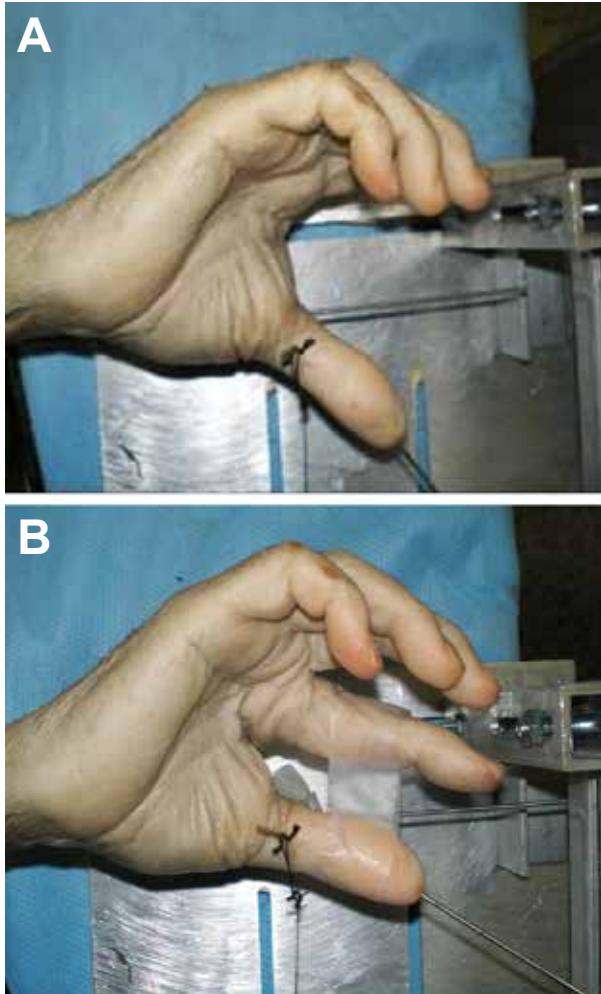


Figure 3. Valgus stress at 30° thumb flexion applied with proper and accessory UCL incised (A), buddy taping of thumb to index (B), a with the index immobilized (C).

Table 1. Thumb valgus laxity values in flexion and extension with all ligaments intact (control) and with incision of proper UCL, buddy taping (BT) of the thumb to the index, and immobilization of the index (IMM).

Stage	Extension (0°) ± SD	30° Flexion ± SD
Control	12.3° ± 3.6	16.0° ± 5.0
Proper UCL incised	33.3° ± 19.0	39.8° ± 18.8
Proper - BT	22.0° (n = 1)	26.0° ± 5.7 (p = 0.18)
Proper - BT + IMM	6.5° ± 4.9 (p = 0.02)	4.7° ± 4.5 (p < 0.01)

DISCUSSION

Partial UCL injuries imply that only the proper UCL is deficient. Complete injuries indicate that both the proper and accessory UCL contributions are torn. Additional deformation of the MCP joint to valgus stress is seen when the volar plate or adductor pollicis is also injured (4).

strength, and length of sick leave between plaster cast and functional splint. Furthermore, functional bracing was preferred by patients (3). Other studies have shown that early motion enhances osteogenesis, promotes revascularization of damaged tissue, and improves the biological process (9). Additional immobilization techniques are a Thermoplast splint (10), a Velcro and felt

Table 2. Thumb valgus laxity values in flexion and extension with incision of proper and accessory UCL, buddy taping (BT) of the thumb to the index, and immobilization of the index (IMM).

Stage	Extension (0°) ± SD	30° Flexion ± SD
Accessory (+ proper) UCL incised	46.7° ± 4.2	44.7° ± 6.4
Accessory - BT	28.5° ± 5.0 (p=0.06)	34.5° ± 14.9 (p=0.549)
Accessory - BT + IMM	8.5° ± 7.8 (p=0.03)	9.5° ± 9.2 (p=0.04)

Treatment is generally nonoperative for sprains or partial ruptures and operative for complete ruptures (3,5-8). Although thumb spica casting is the most common method of immobilization in partial injuries, previous studies have shown that functional bracing is equally effective in managing injuries and is preferred by patients for partial injuries (3).

There was no difference in stability,

construction (11), and a Thermoplast and Velcro combination (12). All of these provide a restraint to radial deviation.

No previous studies have investigated whether buddy taping the thumb to the index finger provides adequate stability in the setting of an injured thumb MCP ulnar collateral ligament. From this study, it is clear that buddy taping significantly reduces the motion (30° with the proper and

Table 3. Thumb valgus laxity values in flexion and extension with incision of proper UCL, accessory UCL, and volar plate, buddy taping (BT) of the thumb to the index, and immobilization of the index (IMM).

Stage	Extension (0°) ± SD	30° Flexion ± SD
Volar plate (+ proper, accessory) incised	50.3° ± 8.7	48.3° ± 3.5
Accessory - BT	37.5° ± 17.7 (p=0.49)	40.7° ± 11.01 (p=0.313)
Accessory - BT + IMM	3.0° ± 4.2 (p<0.01)	0° (p<0.01)

accessory ligaments transected), closer to physiological limits. There is also significant variation in physiological laxity. In extension, valgus laxity ranges from 6° to 15°; it ranges from 12° to 15° in slight flexion (13,14). Whether reducing the valgus laxity to levels of 30° is conducive to allowing healing is not known. Most activities that stress the UCL are key pinch and grip strength. By extension, one theoretical advantage of buddy taping is that the tape itself functions as a barrier to object placement between the thumb and index finger.

Weaknesses of the study include the use of cadavers and a relatively small sample size. In addition, sequential testing of the MCP joint even with buddy taping may give progressively increasing values because elasticity of cadaver tissue may decrease with repetitive loading.

CONCLUSIONS

Buddy taping of the thumb to the index does not appear to provide an adequate reduction of valgus laxity in the setting of an injured UCL, and its clinical use does not appear to be supported by the data from this study.

REFERENCES

1. Campbell CS. Gamekeeper's thumb. *J Bone Joint Surg Br.* 1955;37:148-9.
2. Pichora DR, McMurtry RY, Bell MJ. Gamekeepers thumb: a prospective study of functional bracing. *J Hand Surg.* 1989;14:567-73.
3. Sollerman C, Abrahamsson SO, Lundborg G, Adalbert K. Functional splinting versus plaster cast for ruptures of the ulnar collateral ligament of the thumb. A prospective randomized study of 63 cases. *Acta Orthop Scand.* 1991;62:524-6.
4. McKeon KE, Gelberman RH, Calfee RP. Ulnar collateral ligament injuries of the thumb: phalangeal translation during valgus stress in human cadavers. *J Bone Joint Surg Am.* 2013;95:881-7.
5. Abrahamsson SO, Sollerman C, Lundborg G, Larsson J, Egund N. Diagnosis of displaced ulnar collateral ligament of the metacarpophalangeal joint of the thumb. *J Hand Surg.* 1990;15:457-60.
6. Bowers WH, Hurst LC: Gamekeeper's thumb. Evaluation by arthrography and stress roentgenography. *J Bone Joint Surg Am.* 1977;59:519-24.
7. Rhee PC, Jones DB, Kakar S. Management of thumb metacarpophalangeal ulnar collateral ligament injuries. *J Bone Joint Surg Am.* 2012;94:2005-12.
8. Smith RJ. Post-traumatic instability of the metacarpophalangeal joint of the thumb. *J Bone Joint Surg Am.* 1977;59:14-21.
9. Latta LL, Sarmiento A, Tarr RR. The rationale of functional bracing of fractures. *Clin Orthop.* 1980;146:28-36.
10. Landsman JC, Seitz WH, Froimson AI, Leb RB, Bachner EJ. Splint immobilization of gamekeeper's thumb. *Orthopedics.* 1995;18:1161-5.
11. Fillion PL. Ulnar collateral ligament thumb sling. *J Hand Ther.* 2004;17:69-70.
12. Galindo A, Lim S. A metacarpophalangeal joint stabilization splint: the Galindo-Lim thumb metacarpophalangeal joint stabilization splint. *J Hand Ther.* 2002;15:83-4.

13. Coonrad RW, Goldner JL. A study of the pathological findings and treatment in soft-tissue injury of the thumb metacarpophalangeal joint. With a clinical study of the normal range of motion in one thousand thumbs and a study of post mortem findings of ligamentous structures in relation to function. *J Bone Joint Surg Am.* 1968;50:439-51.
14. Palmer AK, Louis DS. Assessing ulnar instability of the metacarpophalangeal joint of the thumb. *J Hand Surg.* 1978;3:542-6.